

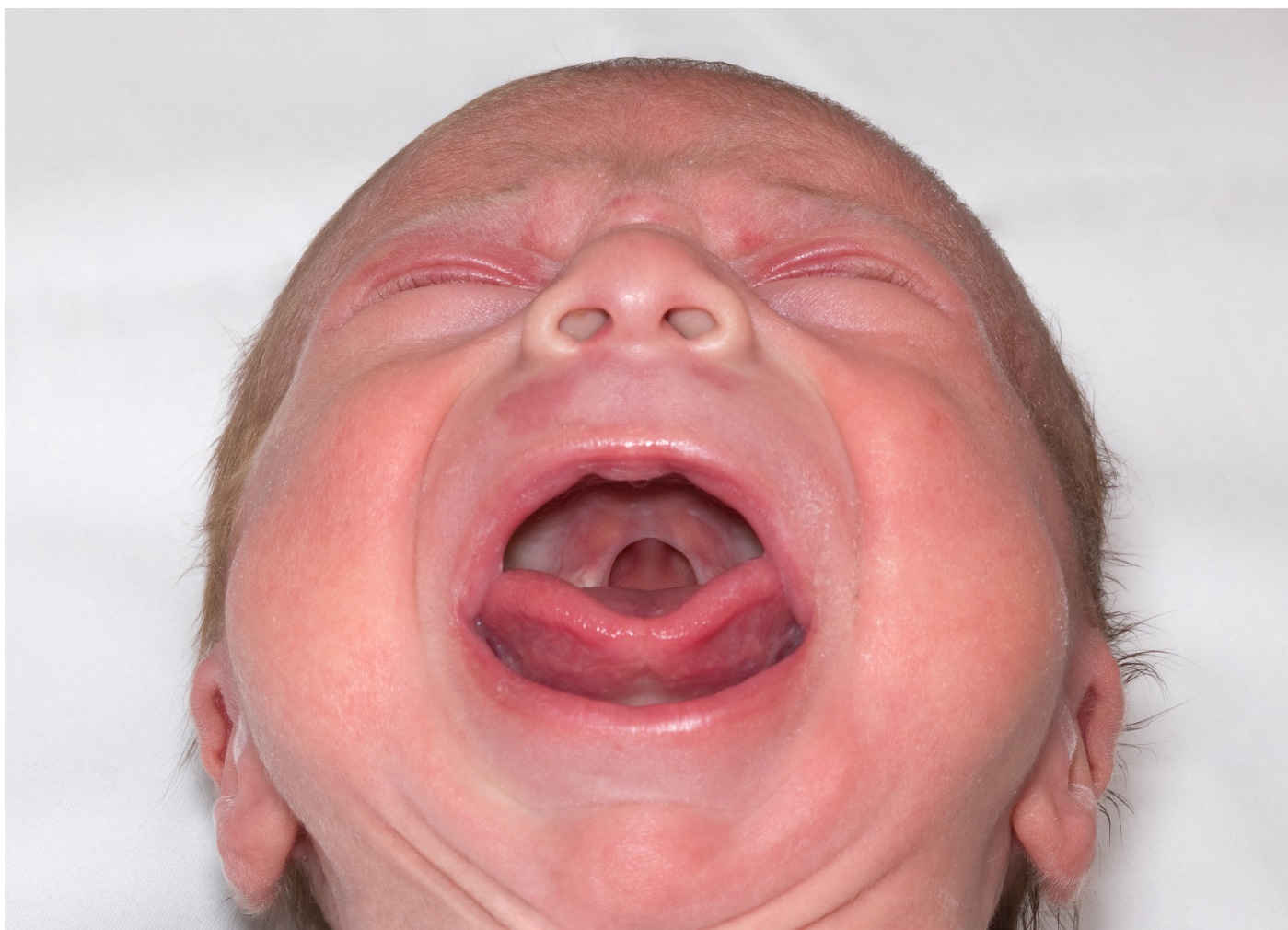

Palate examination: Identification of cleft palate in the newborn

October 2014

British Association of Perinatal Medicine
Cleft Lip and Palate Association
Royal College of General Practitioners
Royal College of Midwives
Royal College of Paediatrics and Child Health
The Craniofacial Society of Great Britain and Ireland


RCPCH
Royal College of
Paediatrics and Child Health
Leading the way in Children's Health



Newborn with cleft of soft palate extending into the hard palate, permission given by John Volcano

Palate examination: Identification of cleft palate in the newborn

October 2014



Authors

- Lindsey Hunter, RCPCH, London
- Alex Habel, Great Ormond Street Hospital, London

Acknowledgements

The guidance working group would like to thank all stakeholders and Delphi panellists for their time and involvement in the project (a full list of which can be found on the RCPCH website).

Mary Dharmachandran (Project Librarian (RCM Collection), Royal College of Obstetricians and Gynaecologists).

Working group

- | | |
|--|---|
| • Jan Dudley, <i>Consultant Paediatric Nephrologist</i> | Chair of the working group |
| • Alex Habel, <i>Honorary Consultant Paediatrician</i> | Clinical Lead |
| • Aung Soe, <i>Consultant Neonatologist</i> | BAPM |
| • Cathy Marsh, <i>Lead Cleft Clinical Nurse Specialist</i> | Nursing SIG Great Britain and Ireland |
| • David Elliman, <i>Community Paediatrician</i> | NIPE Clinical Director |
| • Helen McElroy, <i>Consultant Neonatologist</i> | RCPCH Clinical Standards Committee |
| • Janice Allister, <i>General Practitioner</i> | RCGP |
| • Mandy Tuckey, <i>Parent Representative</i> | Parent Representative |
| • Mervi Jokinen, <i>Practice & Standards Advisor</i> | RCM |
| • Neil Marlow, <i>Consultant Neonatologist</i> | NIPE |
| • Rosanna Preston, <i>CLAPA Chief Executive</i> | Cleft Lip & Palate Association |
| • Rona Slator, <i>Consultant Cleft Surgeon</i> | Craniofacial Society of Great Britain and Ireland & Royal College of Surgeons |

RCPCH team

- Lindsey Hunter, Systematic Reviewer/Project Manager
- Sara Haveron, Clinical Standards Administrator

CONTENTS

1. Introduction	4
1.1 Aim	
1.2 Target audience	
1.3 Target population	
1.4 Guidance limitations	
1.5 Development of the guidance	
1.6 Methods	
1.7 Update of the guidance and audit	
2. Recommendations	6
3. Guideline implementation	6
4. Resource implications	6
5. Key terms	6
6. Reference list	7
Appendix 1: Research recommendations and rationale	8

1. Introduction

A cleft palate occurs when the roof of the mouth has not joined completely. Delay in detection of a cleft palate may adversely affect growth, development and timely medical and surgical management. Delay in diagnosis impacts significantly on parents, leading to anger and disappointment with health care professionals¹. Litigation brought for delayed detection of cleft palate cost the National Health Service £250,000 in a 10 year period².

There is strong circumstantial evidence in the United Kingdom for a culture of inadequate examination of the new-born mouth to detect cleft palate³. This manifests as a delay in detection after the first routine examination has taken place. A prevalence of 30% delayed detection beyond the first 24 hours has not changed significantly over a 10 year period^{3, 4, 5, 6}. In this 30% where delays in detection of cleft palate were found; 12% were delayed more than a week, 7% were in infants under three months of age, 3% under a year old and 2% over one year³. Other UK professionals have reported their concerns about delayed detection in conference proceedings^{7, 8}, however delayed detection is not confined to UK practice^{9, 10}. In one study approximately 50% of Dutch infants with isolated cleft palate were not detected within the national standard examination time period using palpation, and were identified later by visual inspection¹¹.

Although the standard by which newborn examination is completed has changed nationally from 24 hours to 72 hours of age¹², the prevalence of delayed detection remains unacceptable at 16%¹³.

1.1 Aim

This guide provides recommendations to health care professionals for optimal examination of the palate during the routine newborn examination to ensure early detection of a cleft palate.

1.2 Target audience

The target audience for this guide is any healthcare professional who is likely to examine a newborn baby, more specifically, midwifery, neonatal and general paediatricians, general practitioners (GP) and health visitors, as well as more peripherally; dental, ear, nose and throat (ENT), and paediatric respiratory trainees, and allied professionals such as speech and language therapists and paediatric dieticians.

1.3 Target population

Babies from birth to 28 days of age examined routinely as part of the newborn examination, usually within 72 hours of birth, in hospital, at home, or at the general practitioner's (GP) surgery.

1.4 Guidance limitations

This guide provides advice on appropriate methods of detecting cleft palate in babies. While the guide aims to help healthcare professionals in their everyday work it does not replace clinical knowledge and expertise.

1.5 Development of the guidance

The recommendations in this guide have been developed following a systematic review of published literature. The RCPCH standards for development of clinical guidelines in paediatrics and child health¹⁴ were followed to ensure a robust guideline development process and formulation of recommendations. The working group undertook the systematic review with methodological advice from the RCPCH Clinical Standards team. Where there was limited evidence to support recommendations for practice a Delphi consensus method was carried out. In circumstances where the Delphi panel did not reach consensus the recommendations were based on the working group consensus.

The guide has been subject to stakeholder consultation. Feedback and amendments can be viewed on the RCPCH website. The views of parents and families in the development of the guidance were obtained by incorporating a parent onto the guideline working group and including charities and organisations representing parents and carers of babies with cleft palate as stakeholders. A parent and carer guide to this guidance has been developed in consultation with the RCPCH parent advisory group and CLAPA.

1.6 Methods

Full details of the search strategy, evidence tables and Delphi consensus methods can be found on the RCPCH website.

1.7 Update of the guidance and audit

The best practice guide will be reviewed every three years after publication to assess whether all or part of the guide requires updating. Any update of the guide will include a literature review and stakeholder consultation. An audit of the guideline should be carried out in two years.

2. Recommendations

This best practice guide promotes the following six recommendations:

1. Healthcare professionals should examine a baby's hard and soft palate as part of the full newborn physical examination and record this in the child health record.
2. Examination of the baby's palate should be carried out by visual inspection.
3. A torch and method of depressing the tongue should be used to visualise the whole palate.
4. Parents should be informed if the whole palate (including the full length of the soft palate) has not been visualised during the newborn examination.
5. If the whole palate is not able to be visually inspected at first attempt then a further attempt at visual examination should be made within 24 hours.
6. Trusts should provide training on the correct method of visual inspection of the palate to all healthcare professionals required to carry out the newborn examination.

For full details on the rationale behind each recommendation please see appendix 1.

3. Guideline implementation

The best practice guide, along with a parent and carer guide, is available on the RCPCH website and stakeholders websites for download.

The RCPCH is currently developing an educational resource to accompany this guide to aid the implementation of the recommendations and improve detection of cleft palate. This is expected to be completed in 2015 and information will be available on the RCPCH website.

4. Resource implications

It is not envisioned that the recommendations in this guide will have a substantial impact on local resources. The purpose of the recommendations is to aid healthcare professionals' understanding of how to thoroughly examine the baby's palate to ensure that any clefts are detected.

5. Key terms

Cleft palate	When the roof of the mouth has not joined completely.
Newborn examination	A physical examination of a newborn baby (this should be undertaken within 72 hours of birth) ¹² .

6. Reference list

1. Statham H, Solomou W, Green JM. (2001) *When a baby has an abnormality: a study of parents' experiences*. Centre for Family Research, Cambridge University Press: Cambridge.
2. Freedom of Information communication NHS Litigation Authority 2013.
3. Habel A, Elhadi N, Sommerlad B, Powell J. *Delayed detection of cleft palate: an audit of newborn examination*. Arch Dis Child 2006;91:238-240.
4. CRANE Database. Annual Report 2009. London, Clinical Effectiveness Unit, The Royal College of Surgeons of England. www.crane-database.org.uk
5. CRANE Database Progress Report. 2012. London, Clinical Effectiveness Unit, The Royal College of Surgeons of England. www.crane-database.org.uk
6. Butcher S. Cleft palate: The value of early diagnosis. Midwives 2007;10(8):382-83.
7. Freedlander E, Berry M, Searles J. Missed diagnosis of Cleft Palate. Craniofacial Society of Great Britain and Ireland Annual Meeting 2004.
8. Aikman N, Kelsall W. Are we failing parents? Delayed Detection of Cleft Palate. Craniofacial Society of Great Britain and Ireland Annual Meeting 2012.
9. Rozendaal AM, Luijsterburg AJM, Ongkosuwito EM, van den Boogaard M-JH, de Vries E, Hovius SER, Vermeij-Keers C. Delayed diagnosis and underreporting of congenital anomalies associated with oral clefts in the Netherlands: A national validation study. J Plast Reconstr Aesthet Surg 2012;65:780-790.
10. Kubon C, Sivertsen A, Vindenes HA, Abyholm F, Wilcox A, Lie RT. Completeness of registration of oral clefts in a medical birth registry: a population-based study. Acta Obst Gyn Scand 2007;86:1453-1457.
11. van Veen-van der Hoek Mariska, Jedeloo S, Bredero-Boelhauer HH, Balk-Leurs I, Ongkosuwito E. Missed diagnosis in solitary cleft palate. American Craniofacial and Cleft Palate Association Annual Meeting Proceedings 2011.
12. Newborn and Infant Physical Examination. Standards and competencies. UK National Screening Committee 2008.
13. Marsh C. National survey of delayed detection of cleft palate beyond 72 hours of age conducted by UK Cleft Nurse Specialists in 2013. Personal correspondence 2014.
14. RCPCH. (2006). Standards for development of clinical guidelines in paediatrics and child health, 3rd edition.

Appendix 1: Research recommendations and rationale

Recommendation 1: Healthcare professionals should examine a baby's hard and soft palate as part of the full newborn physical examination and record this in the child health record

SIGN grade: D

Delphi statements

- Examination of the palate should take place during the newborn examination.
Consensus achieved: 85% strongly agree (round 1)
- The inspection of the hard and soft palate by visualisation is an integral part of the newborn full physical examination and should be recorded as part of the child health record; training in palatal inspection should be provided alongside training in the conduct of the examination.
Consensus achieved: 92% strongly agree (round 2)

Delphi evidence summary and translation

There was a high level of consensus with both these statements. The working group felt that the high consensus for palate examination occurring in the newborn examination was important and this recommendation should focus on palate examination as a component of the newborn examination. The group felt it was important that this was appropriately recorded in the child health record. Training on how to carry out cleft palate examination was felt to be an issue that needed to be considered separately.

Recommendation 2: Examination of the baby's palate should be carried out by visual inspection

SIGN grade: D

Delphi statements

- Palate examination should be carried out by palpation alone
Consensus achieved: 80% strongly disagree (round 1)
- Palate examination should be carried out by both palpation and visual inspection
Consensus not achieved: 62% strongly agree (round 2)
- In cases where visual inspection is incomplete (so the whole of the palate is not seen) palpation should be carried out and the result be relied upon to determine presence or absence of a cleft
Consensus not achieved: 69% strongly disagree (round 2)
- Digital examination may improve diagnostic accuracy once a cleft has been detected visually
Consensus not achieved: 46% neither agree nor disagree and 46% strongly disagree (round 2)
- Visual inspection of the palate correctly performed is more likely to detect clefts of the palate, excluding submucous clefts, than palpation/digital examination alone.
Consensus achieved: 77% strongly agree (round 2)

Delphi evidence summary and translation

The Delphi panel reached a high consensus that palpation should not be performed alone, however the use of visual inspection along with palpation or digital examination did not reach a consensus between the Delphi rounds. The working group considered the Delphi consensus rates and comments made by the Delphi participants and found the Delphi panel had concerns with the use of palpation and digital inspection methods. Overall the working group felt it was clear from Delphi responses that visual inspection was the preferred method for examining the baby's palate.

Recommendation 3: A torch and method of depressing the tongue should be used to visualise the whole palate

SIGN grade: D

Delphi statements

- A torch and method of depressing the tongue are required to consistently visualise the whole palate
Consensus achieved: 80% strongly agree (round 1)

Delphi evidence summary and translation

The Delphi panel reached a high level of consensus on both statements. The working group felt that the use of a torch and tongue depressor was an effective method for visualising the cleft palate.

Recommendation 4: Parents should be informed if the whole palate (including the full length of the soft palate) has not been visualised during the newborn examination

SIGN grade: D

Delphi statements

- Parents should be informed if the whole palate (including the full length of the soft palate) could not be seen
Consensus achieved: 92% strongly agree (round 2)

Delphi evidence summary and translation

The Delphi panel reached a high level of consensus and the working group agreed that this was an appropriate recommendation.

Recommendation 5: If the whole palate is not able to be visually inspected at first attempt then a further attempt at visual examination should be made within 24 hours. If visualisation is not achieved at the 2nd inspection, a 3rd attempt at visual examination should be made with consideration of referral to paediatric services

SIGN grade: D

Delphi statements

- If the whole palate is not inspected at first attempt then a further attempt at visual inspection should be made within 24 hours
Consensus achieved: 77% strongly agree (round 1)
- Healthcare professionals should delay discharging the baby home until the whole palate has been inspected, or arrange to return for review as soon as practicable.
Consensus not achieved: 69% strongly agree (round 2)

Delphi evidence summary and translation

The Delphi panel were unable to reach consensus on this statement, however the working group considered this statement and felt that the Delphi panel would have reached consensus if the statement did not use the term “arrange to return for review”. The group felt this statement gave the impression that parents would need to return the baby to the unit if a full examination was not possible. The group considered that although a further review was necessary this could occur in a community setting without the need to return the baby to hospital. The group agreed to rephrase the statement to emphasise a further review is needed if a full visual examination of the palate was not able to be completed.

Recommendation 6: Trusts should provide training on the correct method of visual inspection of the palate to all healthcare professionals required to carry out the newborn examination

SIGN grade: D

Delphi statements

- The inspection of the hard and soft palate by visualisation is an integral part of the newborn full physical examination and should be recorded as part of the child health record; training in palatal inspection should be provided alongside training in the conduct of the examination.
Consensus achieved: 92% strongly agree (round 2)

Delphi evidence summary and translation

The Delphi panel reached a high level of consensus on this statement and the working group felt that adequate training should be provided for healthcare professionals in palate examination and detection of cleft palate.



Royal College of
**Paediatrics and
Child Health**

Royal College of Paediatrics and Child Health
5-11 Theobalds Road, London, WC1X 8SH

The Royal College of Paediatrics and Child Health (RCPCH) is a registered charity in England and Wales (1057744) and in Scotland (SC038299).